

7 Manual Therapy of the Muscles

This chapter provides a detailed presentation of the individual muscles, the areas into which pain radiates from them and the manual therapy of the mTrPs and fascias.

The description of each muscle follows a set pattern:

- First, a summary of the anatomy (origin, insertion, innervation) and function is briefly presented in written form and illustrated in the figures. An overview diagram of the respective body region (shoulder, neck, etc., Chapter 7.1 to Chapter 7.9) introduces the individual sections and shows the muscle structures in relation to each other. To be able to distinguish muscular tissue by palpation, it is necessary to maintain an ongoing internal image of the anatomic topography.
- The presentation of referred pain patterns is based on Travell and Simons (1999), Dejung (2009), Baldry (2004), and Irnich (2013) and more than 25 years of personal clinical experience. The areas marked with deep red show where pain is most likely to radiate, while the pale red areas are affected less often. These colors have nothing to do with the intensity of the pain. While the referred pain pattern coincides to this in most people, there are individual variations, which can be quite amazing, and from a phenomenological viewpoint the patient (and what he or she feels) is always right. The “x” in each figure denotes the area(s) where, based on experience, mTrPs occur frequently. In practice, however, the current site of the mTrP must be detected and specifically identified clinically using the essential diagnostic criteria (taut bands of muscle, point of maximal tenderness, and triggering the patient’s known clinical symptoms).
- The category labeled “Symptoms” provides examples of how the disturbance potential of mTrPs specifically impacts everyday life clinically — usually in the form of characteristic pain and dysfunction.
- Under “Provoking factors,” typical situations are given that often lead to the formation or activation of mTrPs. These examples are in no way intended to provide an exhaustive list of all possible situations that can trigger mTrPs; they merely represent a selection, and are intended to sensitize the therapist to give particular attention to these myofascial issues in the history.
- If the respective muscle might cause neuromuscular entrapment, this is noted specifically. It is invaluable to be cognizant of these areas in which the muscular and nervous systems interface, and to use this knowledge in everyday therapeutic practice (Chapter 6.1.2 and Chapter 8).
- In the category, “Tips for the therapist,” clinical pointers “from the practice for the practice” are summarized.
- Under “Recommendations for the patient,” it is noted how the patient can facilitate his or her own myofascial rehabilitation and prophylactically counteract a relapse.
- Following that, the figures demonstrate how manual therapy of the trigger points and fascias using techniques I–IV and autostretching (technique V, which can take place as a home program) are performed. These illustrations serve only as examples — the patient positioning, the placement of the hand, and how to specifically grab the body part under investigation; they are determined by the specific current situation — they can and should be varied depending on circumstances.

7.1 Shoulder

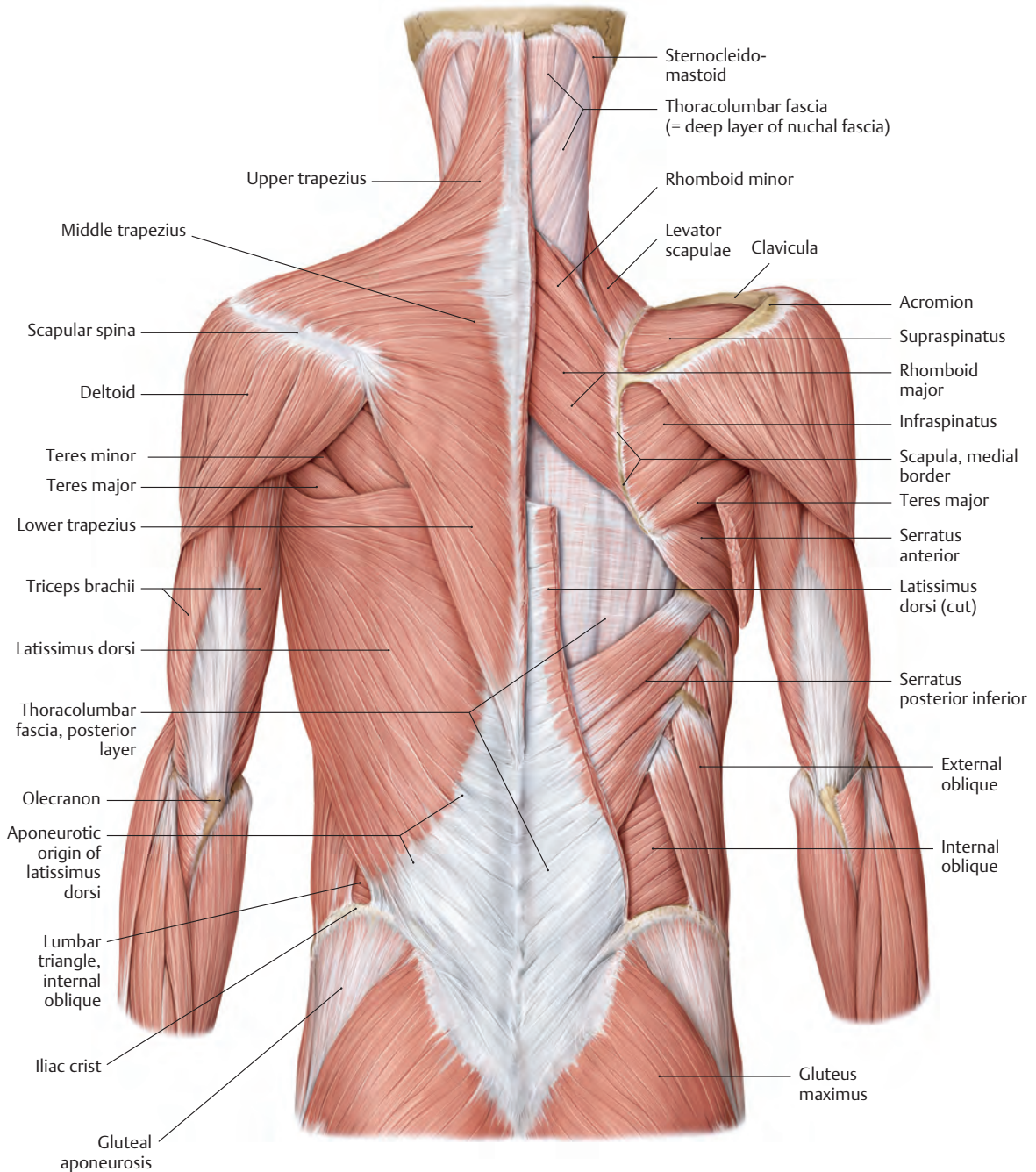


Fig. 7.1 Back, shoulder, and arm muscles: posterior view.

From Schuenke M, Schulte E, Schumacher U. *THIEME Atlas of Anatomy. General Anatomy and Musculoskeletal System*. Illustrations by Voll M and Wesker K. Second Edition. New York: Thieme Medical Publishers; 2014

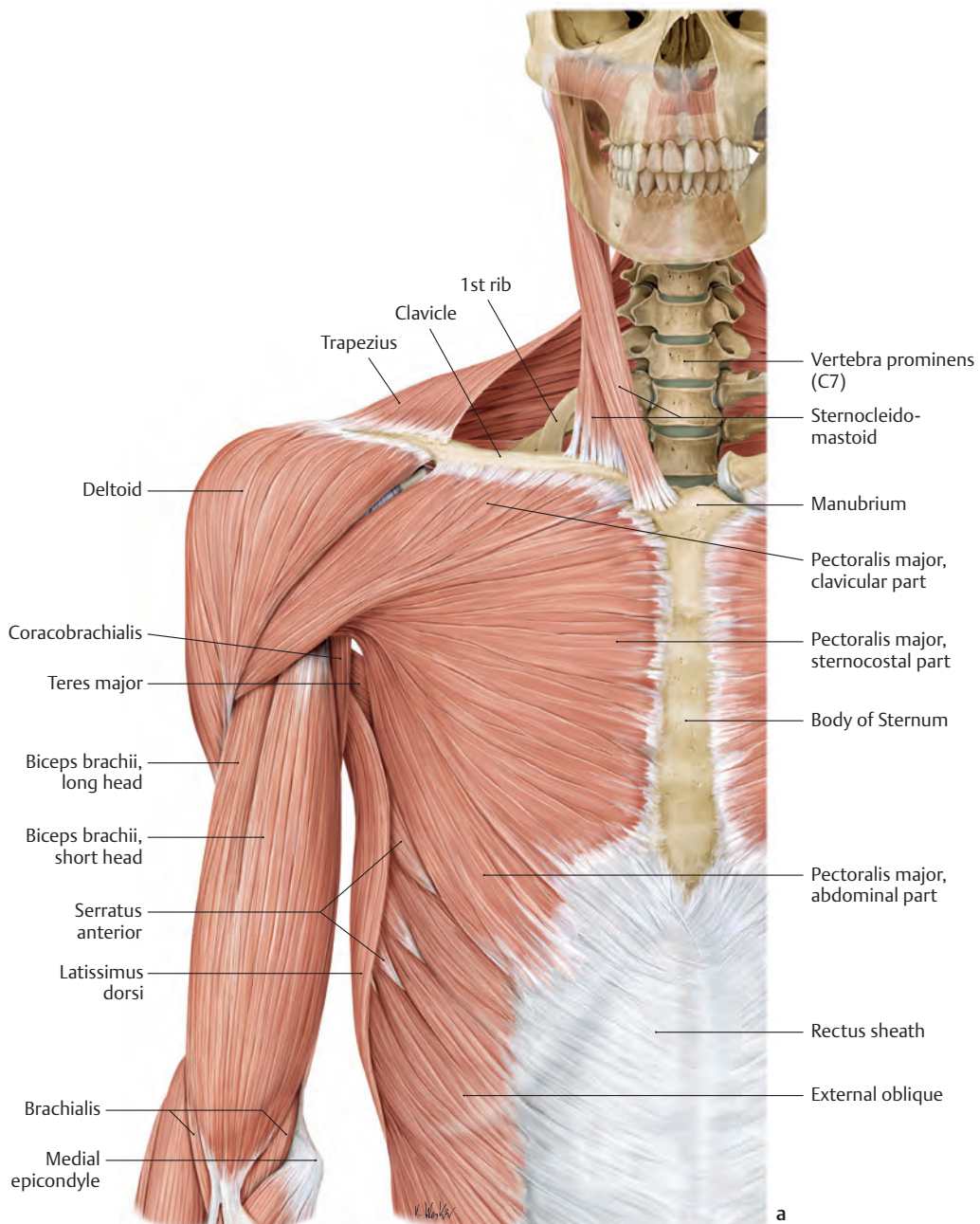


Fig. 7.2 Shoulder and arm muscles: anterior view.

a Superficial layer.

From Schuenke M, Schulte E, Schumacher U. THIEME Atlas of Anatomy. General Anatomy and Musculoskeletal System. Illustrations by Voll M and Wesker K. Second Edition. New York: Thieme Medical Publishers; 2014

Continuation ►

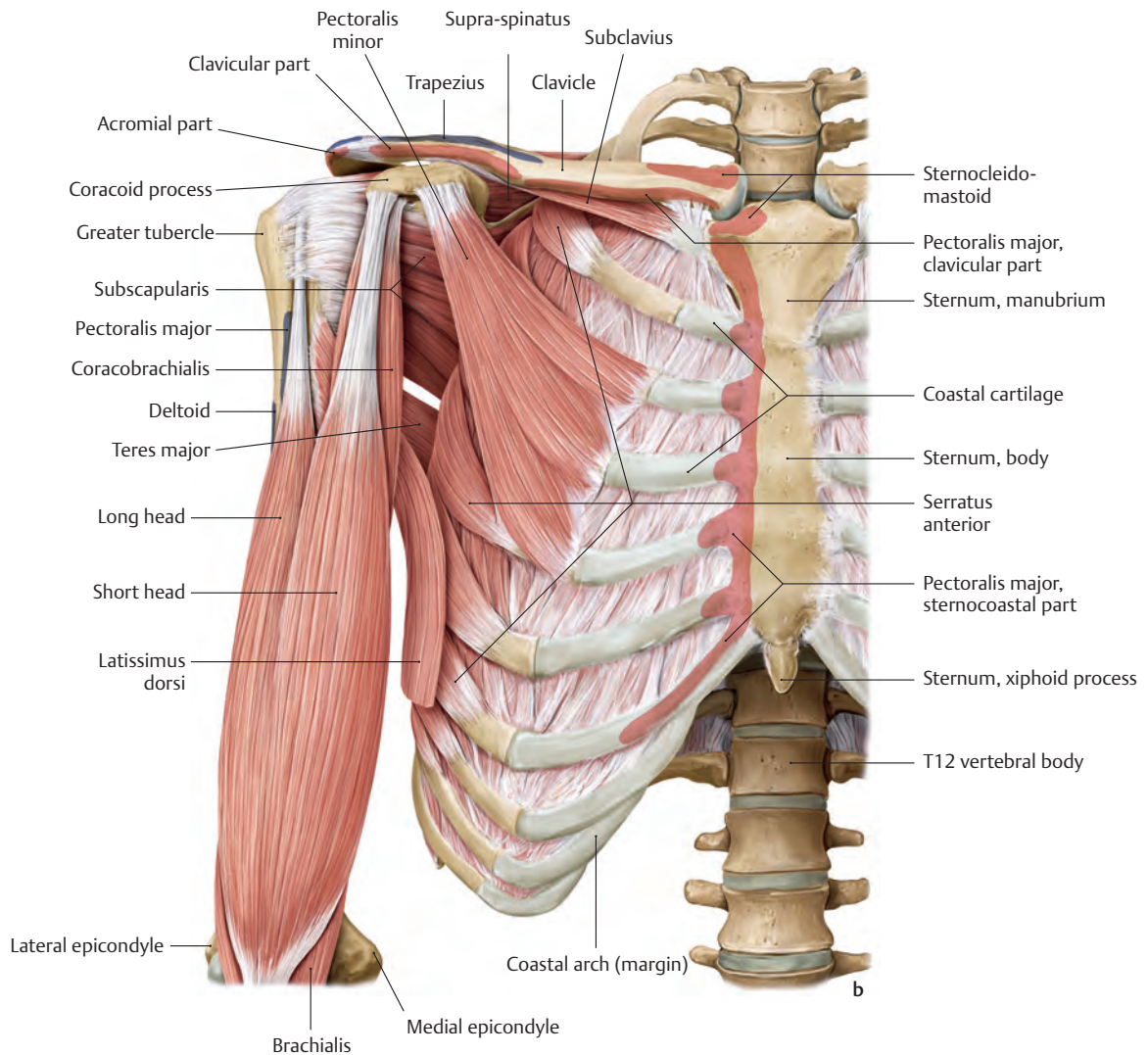


Fig. 7.2 (Continuation) Shoulder and arm muscles: anterior view.

b Deep layer.

From Schuenke M, Schulte E, Schumacher U. THIEME Atlas of Anatomy. General Anatomy and Musculoskeletal System. Illustrations by Voll M and Wesker K. Second Edition. New York: Thieme Medical Publishers; 2014

7.1.1 Deltoid

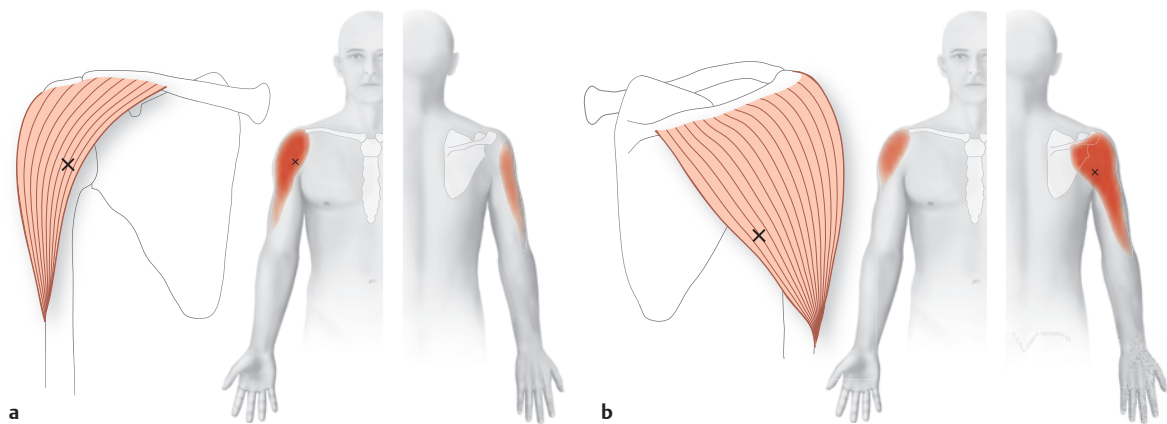


Fig. 7.3 Deltoid.

Anatomy (► Fig. 7.1, ► Fig. 7.2 a)	Origin	<ul style="list-style-type: none"> • Anterior part (clavicular part): from the lateral third of the clavicle • Lateral part (acromial part): from the acromion • Posterior part (spinal part): from the inferior border of the spine of the scapula
	Insertion	<ul style="list-style-type: none"> • Deltoid tuberosity of the humerus • The subdeltoid bursa is located under the deltoid muscle in the greater tubercle area.
	Innervation	<ul style="list-style-type: none"> • Axillary nerve (C5–C6); clavicular part additionally from the pectoral branches (C4–C6)
Function	<ul style="list-style-type: none"> • The three parts of the deltoid function in part synergistically and in part antagonistically. • If all three parts are active at the same time: ABD at the glenohumeral joint (both in the initial abduction as well as incrementally during the entire abduction). • When the anterior and posterior parts act in isolation, they act antagonistically: 	
	Anterior part only	<ul style="list-style-type: none"> • Horizontal ADD (anteversion) • Flexion • IR (not verified by EMG)
	Posterior part only	<ul style="list-style-type: none"> • Horizontal ABD (retroversion) • Extension • ER (not verified by EMG)
	<ul style="list-style-type: none"> • With the arm hanging down, the deltoid (along with the supraspinatus and coracobrachialis) prevents the humeral head from gliding caudal. 	
Referred pain (► Fig. 7.3)	<ul style="list-style-type: none"> • Predominantly local 	
Symptoms	Pain	<ul style="list-style-type: none"> • Primarily with movement of the arms (rarely at rest)
	Dysfunction	<ul style="list-style-type: none"> • Weakness: difficulty in raising the arm above the horizontal • Limited range of motion (ROM) <ul style="list-style-type: none"> ◦ Of horizontal ADD (when the posterior part is affected) ◦ Of horizontal ABD and bringing the hand behind the lower back (when the anterior part is affected)
Provoking factors	Direct trauma	<ul style="list-style-type: none"> • Few other muscles suffer powerful impacts as frequently as the deltoid; the impact presses the muscle directly against the underlying bone. Bumping into door frames; sports activities, etc.
	Overload	<ul style="list-style-type: none"> • Acute: absorbing or preventing a fall • Chronic <ul style="list-style-type: none"> ◦ Overload in sports activities (e.g., cross-country skiing, swimming) ◦ Repeated and prolonged work above the head (e.g., holding a power tool at shoulder height) ◦ PC keyboard that is too high ◦ Sorting mail into shoulder-high mail boxes, etc.
	TrP activity in other muscles	<ul style="list-style-type: none"> • The anterior part of the deltoid lies within the referred pain area of the supraspinatus, infraspinatus, and subscapularis → satellite TrPs in the deltoid.

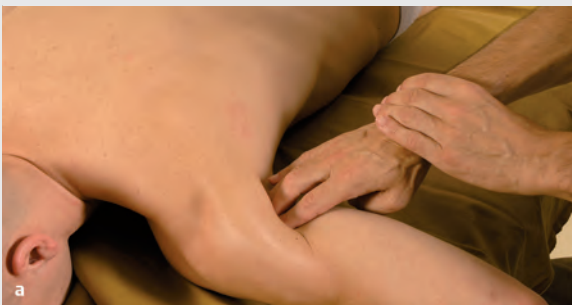
Tips for the therapist	<ul style="list-style-type: none"> • One of the muscles that exhibits TrPs very frequently • Suitable patient positioning for treatment: lateral position (for the lateral and posterior parts of the muscle; ▶ Fig. 7.4); supine position (for the anterior part; ▶ Fig. 7.5); prone position (for the posterior part); sitting position (for all parts of the muscle) • Most of the TrPs are near the anterior and posterior margins of the muscle, at the place where the pectoralis major (anteriorly) and the long head of the triceps (posteriorly) pass under the deltoid → fascial separation technique is helpful (▶ Fig. 7.6) • The insertion site on the humerus (deltoid tuberosity) should also be treated • Usually only minimal radiation → TrPs lie embedded within the referred pain area • When necessary, treat primary TrPs in the supraspinatus, infraspinatus, and subscapularis, because deltoid TrPs may be satellite TrPs
Recommendations for the patient	<ul style="list-style-type: none"> • Avoid perpetuating and provoking factors • TrPs may be self-treated with the opposite hand or with a tennis ball (posterior part) • Stretching (home program; ▶ Fig. 7.7)

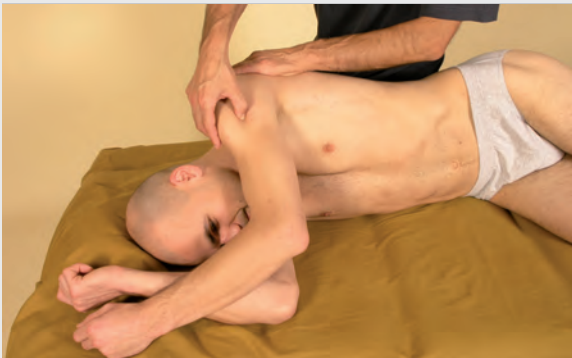

Fig. 7.4 Manual compression (technique I) and stretching the TrP-region (technique II) – posterior part of the deltoid.

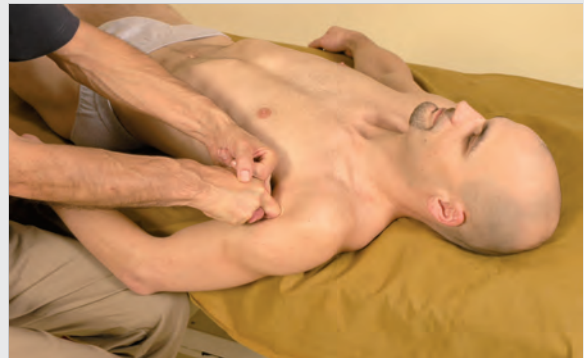

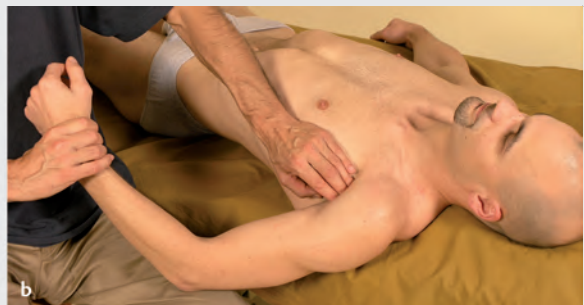Fig. 7.5 Fascial stretching (technique III) of the fiber tracts of the anterior part of the deltoid.



a

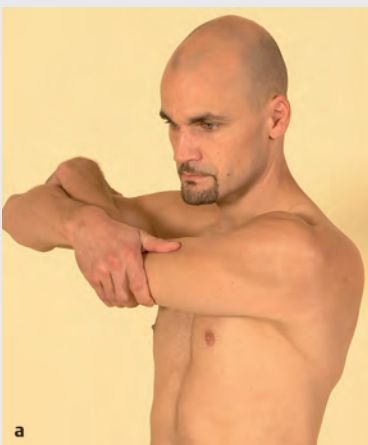

b

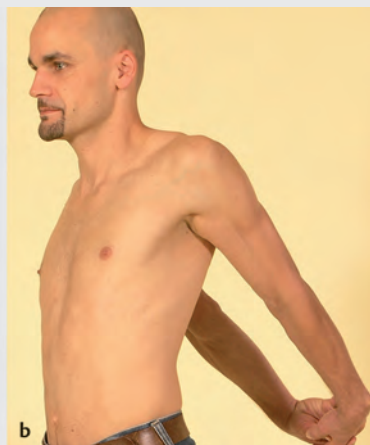Fig. 7.6 Fascial separation (technique IV).

a Fascial separation technique between the deltoid (posterior part) and the long head of the triceps brachii.

b Fascial separation technique between the deltoid (anterior part) and the pectoralis major.



a



b

Fig. 7.7 Self-stretching the deltoid (technique V).

a Autostretching the posterior part.

b Autostretching the anterior part.

7.1.2 Supraspinatus

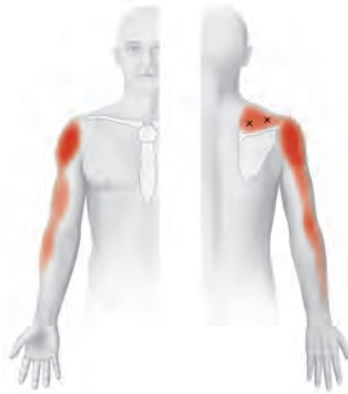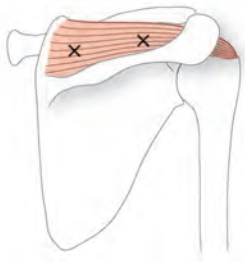


Fig. 7.8 Supraspinatus.

Anatomy (► Fig. 7.1, ► Fig. 7.350)	Origin	<ul style="list-style-type: none"> • Supraspinous fossa, supraspinous fascia
	Insertion	<ul style="list-style-type: none"> • Greater tubercle of the humerus (proximal facet) • Participates in the formation of the rotator cuff
	Innervation	<ul style="list-style-type: none"> • Suprascapular nerve (C 4–C 6)
Function	Glenohumeral joint (shoulder joint)	<ul style="list-style-type: none"> • ABD • Centers the humeral head within the glenoid cavity and tightens the capsule • When the arm is hanging down freely, it holds the humeral head in the joint socket
Referred pain (► Fig. 7.8)		<ul style="list-style-type: none"> • Primarily in the deltoid region (anterior, lateral, and posterior parts) • Radiation distally: laterally along the upper arm with emphasis on the elbow (lateral epicondyle), rarely to the wrist
Symptoms	Pain	<ul style="list-style-type: none"> • Shoulder pain anteriorly, laterally, and posteriorly; deep “in the shoulder” • Increase in pain during abduction • Dull pain at rest; pain at night when lying on the affected shoulder • Bringing the hand behind the lower back is painful • Can participate in impingement symptomatology • Similar to subdeltoid bursitis • Epicondylagia
	Dysfunction	<ul style="list-style-type: none"> • Difficulty with combing hair, brushing teeth, shaving; sports activities: hitting the tennis ball • “Crackling noises” in the shoulder because of poor centering of the humeral head
Provoking factors	Overload	<ul style="list-style-type: none"> • Acute: shoulder trauma (e.g., a fall on the shoulder) • Chronic <ul style="list-style-type: none"> ◦ Carrying heavy objects with arm hanging down at the side (suitcase: salespersons or workmen) ◦ Shoulder abduction syndrome ◦ Repetitive movements in approximated position of the muscle, e.g., working for a long time over the head level (painters, electricians). ◦ Overload from too much computer work ◦ A dog repeatedly straining at the leash
	Primary TrPs	<ul style="list-style-type: none"> • Lower trapezius
Tips for the therapist		<ul style="list-style-type: none"> • Treatment should usually be performed through the trapezius. <ul style="list-style-type: none"> → The trapezius should be relaxed to allow the fingers to probe deeply (► Fig. 7.9). → Wooden trigger point tools may be used as assistive devices (► Fig. 7.10, ► Fig. 7.11). • The anterior fiber components can be treated directly: Approach anteriorly using technique IV between the anterior margin of the upper trapezius and the supraspinatus. The fibers of the upper trapezius must be approximated and relaxed, allowing the fingers to probe deeply (► Fig. 7.12). • Suitable patient positioning for treatment is prone, lateral, or sitting. • For TrPs in the supraspinatus, infraspinatus, and teres minor, always examine the insertion area over the greater tubercle for ligamentous and periosteal trigger points, and treat these if present. • Accompanied by impingement-symptoms

Recommendations for the patient

- Avoid perpetuating and provoking factors
 - Avoid working over the head level for long periods
 - Avoid carrying heavy loads (suitcases) with the arms down (use rolling suitcases)
 - Assume a relaxed posture; e.g., put the hand in the jacket pocket; rest the hand on the table or back of chair
- Self-treatment (“hooking into” the muscle using the fingertips of the opposite hand)
- Stretch the muscles regularly (bringing the hand behind the lower back); ▶ Fig. 7.13)

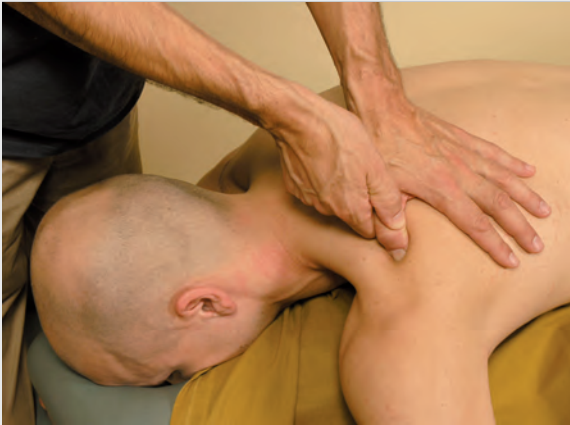

Fig. 7.9 Manual compression (technique I) through the upper trapezius.

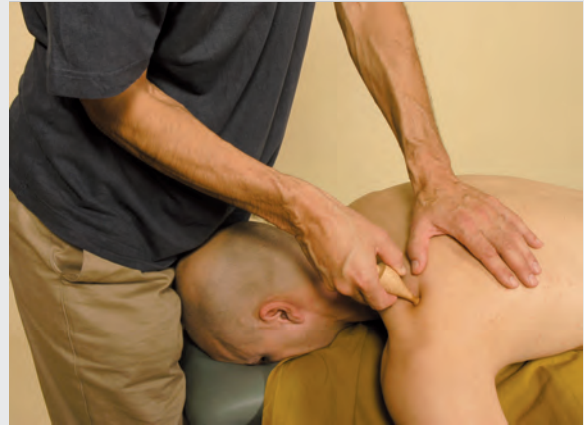

Fig. 7.10 Stretching the TrP-region (technique II) through the trapezius; using a wooden trigger point tool allows the therapist's fingers to relax.

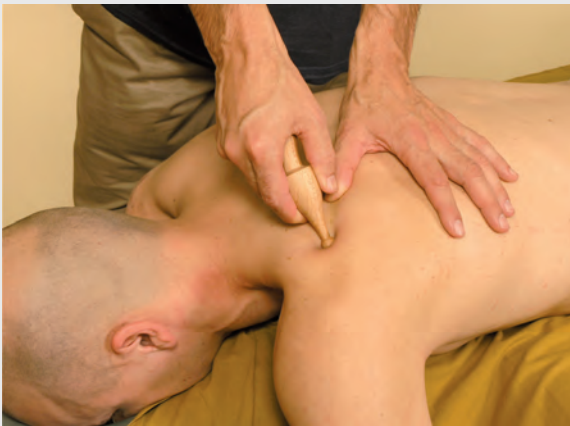

Fig. 7.11 Fascial stretching (technique III) through the trapezius.

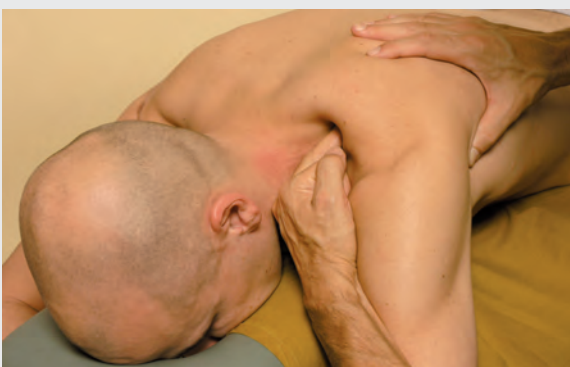


Fig. 7.12 Fascial separation (technique IV) between the supraspinatus and trapezius; this enables direct treatment of the anterior fibers of the supraspinatus (techniques I and II).

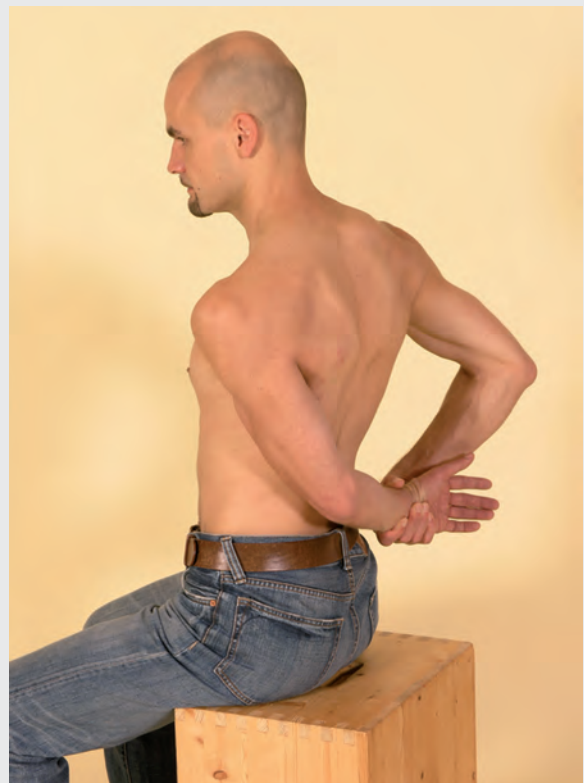

Fig. 7.13 Self-stretching (technique V) of the supraspinatus by bringing the hand behind the lower back.

7.1.3 Infraspinatus

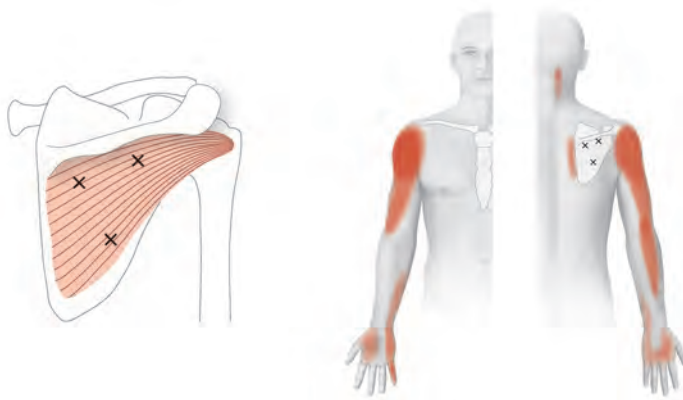


Fig. 7.14 Infraspinatus.

Anatomy (► Fig. 7.1, ► Fig. 7.350)	Origin	<ul style="list-style-type: none"> Infraspinous fossa
	Insertion	<ul style="list-style-type: none"> Greater tubercle of the humerus (middle facet) Participates in the formation of the rotator cuff
	Innervation	<ul style="list-style-type: none"> Suprascapular nerve (C5–C6)
Function	Glenohumeral joint (shoulder joint)	<ul style="list-style-type: none"> ER of the humerus at the shoulder joint (in all positions of the upper arm) ADD of the humerus at the shoulder joint (lateral fibers, with the arm abducted) Centers the humeral head within the glenoid cavity (part of the rotator cuff)
Referred pain (► Fig. 7.14)		<ul style="list-style-type: none"> Anterior part of the shoulder Deep within the shoulder joint Radiation distally to anterolateral upper arm and forearm (including the elbow: primarily radial side) to the radial and ulnar sides of the hand and fingers
Symptoms	Pain	<ul style="list-style-type: none"> In the shoulder area: anterior and deep in the shoulder joint; painful biceps tendon Night pain when sleeping on the side, whether the affected arm is under the body or above it)
	Dysfunction	<ul style="list-style-type: none"> Restricted ability to reach around to the back (difficulty hooking a bra, zipping up a dress in back, taking a wallet out of the back pocket, slipping the arm into a jacket, etc.) Weakness of active external rotation, shoulder fatigue
Provoking factors	Overload	<ul style="list-style-type: none"> Acute: Shoulder trauma (e.g., slipping on the steps: reaching for the railing; missing the ball with a tennis racquet) Chronic <ul style="list-style-type: none"> Repetitive reaching backward (e.g., reaching for the seat belt; always slipping the same arm into the jacket) Using poles when alpine or nordic skiing Activation of the muscle for long periods in a shortened, contracted position → activation of mTrPs, e.g., working on a computer, typewriter, cash register, etc.
	TrP activity in other muscles	<ul style="list-style-type: none"> TrPs in the subscapularis often give rise to associated TrPs in the infraspinatus muscle.
Tips for the therapist		<ul style="list-style-type: none"> Activation for long periods in a shortened, contracted position strongly facilitates the formation and activation of mTrPs (working on a computer, etc.) → listen carefully for this during the history Suitable patient positioning for treatment: prone (► Fig. 7.15–► Fig. 7.18) or lateral position To relieve the fingers, the therapist should stabilize the finger well and occasionally change fingers — don't always use thumb pressure! (► Fig. 7.15, ► Fig. 7.16, ► Fig. 7.17 a, see also ► Fig. 5.7); use wooden trigger point tools if need be. Fascial stretching (technique III) can be used selectively to target the fibers of the TrP-associated taut bands (► Fig. 7.17 a) or more broadly to stretch out wide areas of the superficial fascia of the associated muscle (► Fig. 7.17 b). For TrPs in the supraspinatus, infraspinatus, and teres minor, always examine the insertion area over the greater tuberosity for ligamentous and periosteal trigger points, and treat these if present. When necessary, treat primary TrPs in the subscapularis (common).

Recommendations for the patient

- Avoid perpetuating and provoking factors
 - Break up long, monotonous periods of workplace strain (computer)
- Stretch the muscles regularly at work (► Fig. 7.19)
- Self-treatment of TrPs with a tennis ball (standing against the wall or supine on the floor)

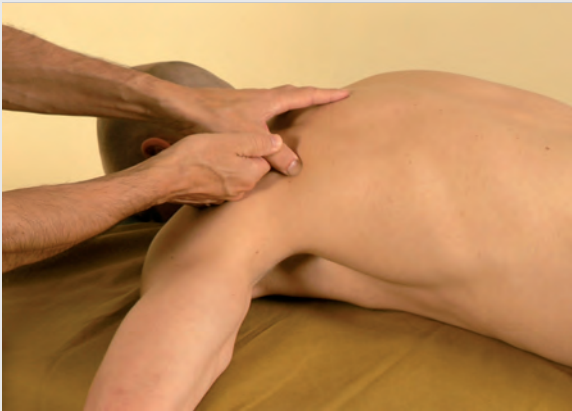

Fig. 7.15 Manual compression (technique I).

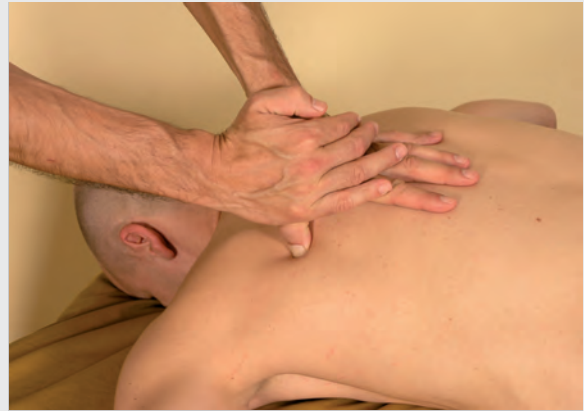
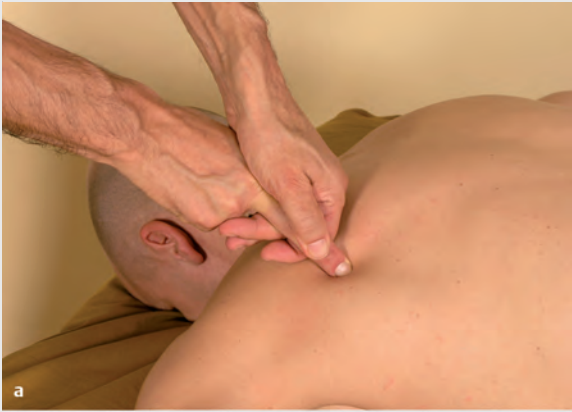
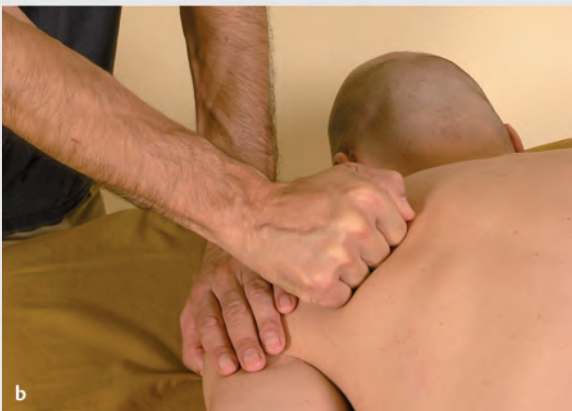Fig. 7.16 Stretching the TrP-region (technique II).



a



b

Fig. 7.17 Fascial stretching (technique III).
 a Stretching the TrP-associated taut bands selectively.
 b Broad stretching of the muscle fibers of the infraspinatus.

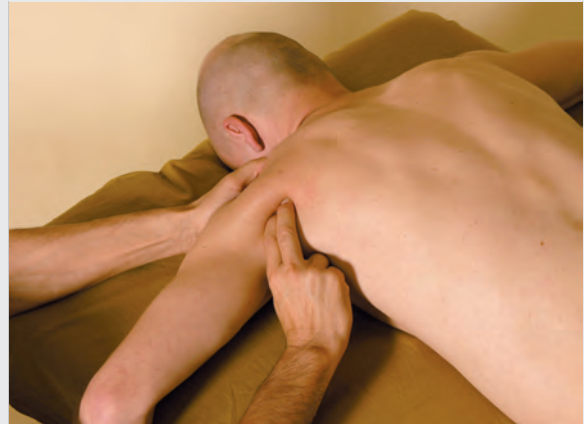

Fig. 7.18 Fascial separation between the infraspinatus and the spinal part of the deltoid (technique IV).



Fig. 7.19 Self-stretching (technique V).

7.1.4 Teres Minor

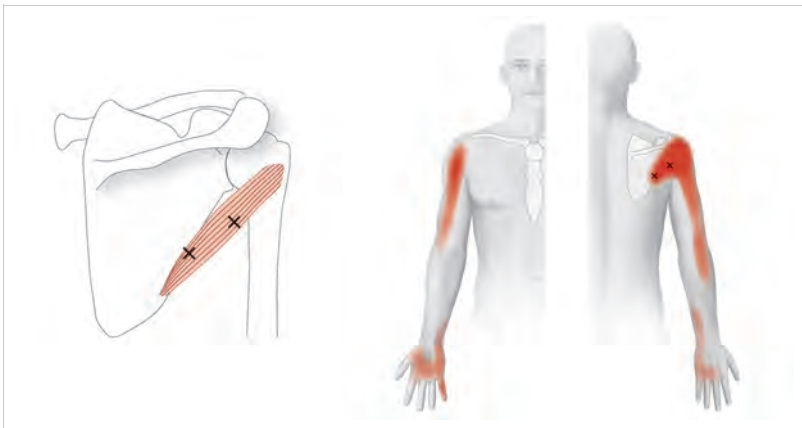


Fig. 7.20 Teres minor.

Anatomy (► Fig. 7.1, ► Fig. 7.350)	Origin	<ul style="list-style-type: none"> • Lateral border of the scapula (superior to that of the teres major) • Aponeuroses that divide it from the infraspinatus and teres major
	Insertion	<ul style="list-style-type: none"> • Greater tubercle of the humerus (distal facet) • Participates in the formation of the rotator cuff
	Innervation	<ul style="list-style-type: none"> • Axillary nerve (C5–C6)
Function	Glenohumeral joint (shoulder joint)	<ul style="list-style-type: none"> • ER of the humerus at the shoulder (high rotation) • ADD of the humerus at the shoulder (from abducted arm position) • As part of the rotator cuff, participates in centering the humeral head
Referred pain (► Fig. 7.20)		<ul style="list-style-type: none"> • Posterior and anterior shoulder, clearly distal to the subacromial bursa • Radiates distally to the posterolateral upper arm and forearm, including the elbow
Symptoms	Pain	<ul style="list-style-type: none"> • Shoulder and arm areas, occasional elbow pain
	Dysfunction	<ul style="list-style-type: none"> • Restricted ability to reach around to the back (difficulty hooking a bra, zipping up a dress in back, taking a wallet out of the back pocket, slipping the arm into a jacket, etc.)
Provoking factors	Overload (same as infraspinatus)	<ul style="list-style-type: none"> • Acute <ul style="list-style-type: none"> ◦ Slipping on the steps: reaching for the railing ◦ Missing the ball with a tennis racquet • Chronic <ul style="list-style-type: none"> ◦ Frequently reaching backward (e.g., repeatedly reaching back to get a wallet out of the back pocket; always slipping the same arm into the jacket) ◦ Using poles when alpine or nordic skiing ◦ Activation for long periods in a shortened, contracted position → activation of mTrPs (e.g., working on a computer, typewriter, or cash register)
Tips for the therapist		<ul style="list-style-type: none"> • Activation for long periods in an approximated, contracted position strongly facilitates the development and activation of mTrPs → listen for this carefully during the history. • Suitable patient positioning for treatment is prone (► Fig. 7.21–► Fig. 7.23) or lateral position. • It is important to use the manual fascial separation technique (technique IV) to separate the teres minor and major (they are antagonistic regarding the rotational component) (► Fig. 7.23, Fig. 7.35). • The teres minor and infraspinatus are often fused; the two muscles can sometimes barely be differentiated by means of palpation. • When mTrPs are present in the supraspinatus, infraspinatus, and teres minor, always examine the insertion area over the greater tubercle for ligamentous and periosteal trigger points, and treat these if present.
Recommendations for the patient		<ul style="list-style-type: none"> • Avoid perpetuating and provoking factors <ul style="list-style-type: none"> ◦ Break up long, monotonous periods of workplace strain (computer work) • Self-treatment of TrPs using a tennis ball • Stretch the muscle regularly at work; stretch it together with the infraspinatus (► Fig. 7.19)

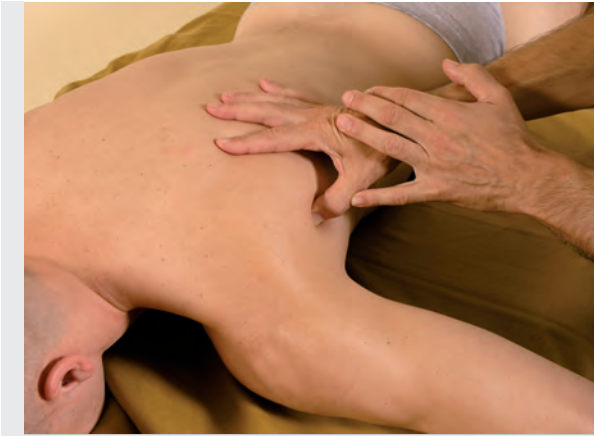


Fig. 7.21 Manual compression (technique I) or stretching the TrP-region (technique II).

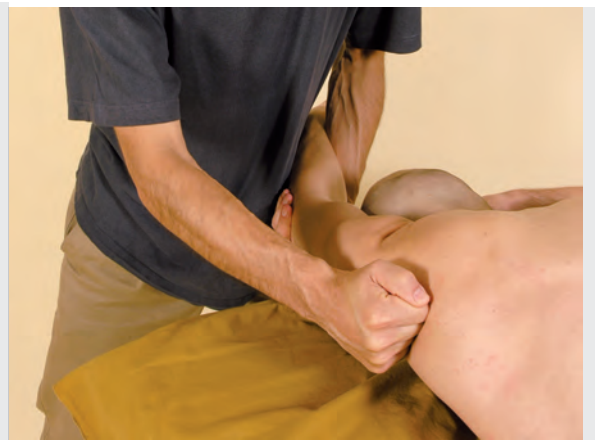

Fig. 7.22 Fascial stretching (technique III).

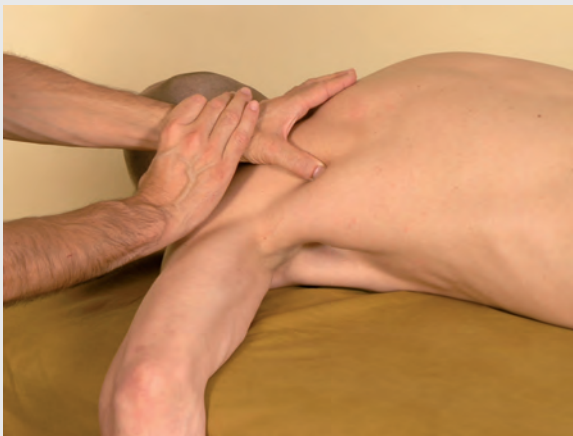

Fig. 7.23 Fascial separation (technique IV) between the teres minor and teres major.

7.1.5 Subscapularis

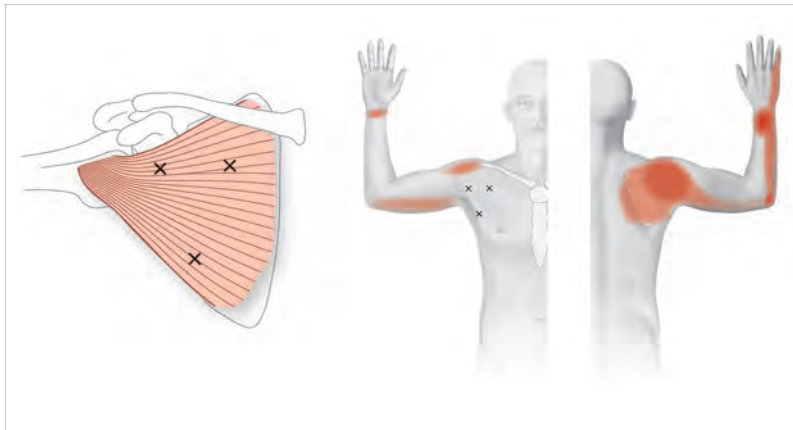


Fig. 7.24 Subscapularis.

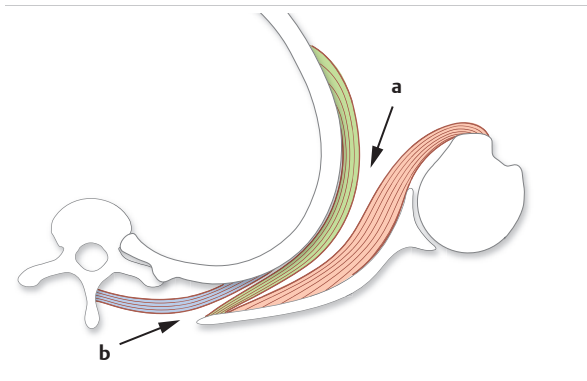


Fig. 7.25 Approach to the subscapularis

- a** Lateral approach, from the lateral border of the scapula: Initially, release adhesions, which are frequently quite pronounced, between the fascias of the subscapularis (brown) and the serratus anterior (green) carefully and persistently using the fascial separation technique (technique IV). Only then are the TrPs in the subscapularis accessible for direct manual treatment using techniques I, II, and III (► Fig. 7.26, ► Fig. 7.27). Only in the distal area can a small part of the muscle be treated directly without hindrance (► Fig. 7.28).
- b** Posterior approach, from the medial border of the scapula: Treatment takes place through the trapezius, the rhomboids, and the serratus anterior (► Fig. 7.29).

Anatomy (► Fig. 7.2 b, ► Fig. 7.351)	Origin	<ul style="list-style-type: none"> • Subscapular fossa: anterior surface of the scapula
	Insertion	<ul style="list-style-type: none"> • Lesser tubercle of the humerus, proximal part of the crest of the lesser tubercle • Extends into the anterior parts of the joint capsule • Participates in the formation of the rotator cuff
	Innervation	<ul style="list-style-type: none"> • Subscapular nerves (C5–C6)
Function	Glenohumeral joint (shoulder joint)	<ul style="list-style-type: none"> • IR (the primary internal rotator) • ADD • Centers the humeral head within the glenoid cavity • Pulls the head of the humerus inferiorly during abduction • Tightens the capsule <p>During abduction, corresponding to the vertical vector of the direction of movement, the deltoid pulls the head of the humerus out of the glenoid cavity and upward against the acromion. During abduction, the function of the subscapularis pulling downward acts as the main force acting against this upward shift caused by abduction. This stabilizing function of the subscapularis is detectable by the electromyographic activity of the subscapularis during abduction, which increases from 0° to 90°, remains constant from 90° to 130° and decreases very quickly between 130° and 180°, when the deltoid no longer exerts upward directed force (Travell and Simons 1999).</p>
Referred pain (► Fig. 7.24)		<ul style="list-style-type: none"> • Posterior shoulder area (to the posterior part of the deltoid and to the infraspinatus muscle) • Radiates distally: posteriorly along the upper arm to the elbow and frequently to the wrist (“CTS”), occasionally into the fingers, especially to the little finger side

Symptoms	Pain	<ul style="list-style-type: none"> • Severe pain in the referred pain area, both at rest and with movement • Paresthesias (“falling asleep,” tingling, heavy sensation) in the entire arm are possible
	Dysfunction	<ul style="list-style-type: none"> • Limited ROM <ul style="list-style-type: none"> ◦ ER, ABD restricted at end-range; initially, primarily ER affected (reaching back during throwing motions); in advanced stages, ABD affected as well → frozen shoulder (difficulty washing the armpits) ◦ Scapulothoracic gliding space restricted due to fascial adhesion between the subscapularis and serratus anterior → restricted ROM and disturbance of the scapulohumeral rhythm • Disturbance of the arthrokinematics of the glenohumeral joint: caudal gliding does not work → participation in the impingement syndrome
Provoking factors	Overload	<ul style="list-style-type: none"> • Acute <ul style="list-style-type: none"> ◦ Falling and catching oneself on the outstretched hands ◦ Associated with shoulder dislocation ◦ Sports: e.g., a European handball player who is blocked on the throwing arm • Chronic <ul style="list-style-type: none"> ◦ Repeated exertion (e.g., crawling) ◦ Prolonged work above the head (e.g., painters, electricians) ◦ In conjunction with fractures of the upper extremity (humerus, elbow, radius) ◦ Over time, assuming an antalgic posture (IR/ADD) to ease chronic shoulder pain causes the activation of TrPs ◦ Spastic: hemiplegic shoulder
	Overstretching	<ul style="list-style-type: none"> • Overstretching during surgery or radiation (e.g., for carcinoma of the breast)
Tips for the therapist	<ul style="list-style-type: none"> • The subscapularis is a key muscle in chronic shoulder problems (Dejung 2009). • Limited ROM with respect to: <ul style="list-style-type: none"> ◦ ABD → the lateral fibers of the subscapularis are primarily responsible. ◦ IR → transverse fibers are primarily responsible. • Fascial separation technique (technique IV) to the serratus anterior is important in cases of restricted mobility of the scapulothoracic gliding space (► Fig. 7.26, ► Fig. 7.27). • TrPs are induced reciprocally in the subscapularis and serratus anterior. • Approach to the subscapularis is possible from: <ul style="list-style-type: none"> ◦ Laterally: approach from the lateral border of the scapula (between the scapula and the thorax); carefully and persistently release adhesions (often quite prominent) between the fibers of the subscapularis and serratus anterior using the fascial separation technique (technique IV). Only then are the TrPs in the subscapularis accessible for direct manual treatment using techniques I, II, and III (► Fig. 7.26, ► Fig. 7.27). In the distal area of the subscapularis, a small part of the muscle can be treated directly (► Fig. 7.28) without treating the serratus anterior with technique IV beforehand (► Fig. 7.25). ◦ Medially: from posteriorly, working from the medial border of the scapula: Treatment takes place through the trapezius, the rhomboids, and the serratus anterior (Fig. 7.29, ► Fig. 7.82–► Fig. 7.84). • Suitable patient positioning for treatment: <ul style="list-style-type: none"> ◦ Lateral approach: supine position (► Fig. 7.26, ► Fig. 7.27), lateral position ◦ Medial approach: lateral (► Fig. 7.29 a and c, ► Fig. 7.84), prone position (► Fig. 7.29 b, ► Fig. 7.82) • The lateral approach is contraindicated after irradiation to the axilla (radiation fibrosis) until after the radiation reaction subsides (about one year), because a massive reaction, with pain and lymphedema of the whole arm, can occur, presumably due to the demands of the additional lymph load, which overwhelms the already-compromised lymphatic drainage system; an elevated myoglobin level is detectable after treatment using intense pressure (► Fig. 5.24). • Regular and consistent stretching (after manual therapy) is often crucial for therapeutic success when treating cases in which the rotational components of movement are restricted (frozen shoulder) (► Fig. 7.30). • If the insertion site on the lesser tubercle is tender to palpation, it should also be treated. • Manual therapy of the subscapularis should be combined with mobilization of the scapulothoracic gliding space: lift (“air out”) the scapula (► Fig. 7.82–► Fig. 7.86). • TrPs in the subscapularis can be responsible for lateral epicondylalgia. • Primary TrPs are often found in the subscapularis, which frequently cause the development of associated TrPs: <ul style="list-style-type: none"> ◦ Secondary TrPs in synergists (teres major, latissimus dorsi, pectoralis major) and antagonists (infraspinatus, teres minor, supraspinatus, and deltoid) ◦ Satellite TrPs in the deltoid (posterior part), triceps brachii and the anconeus 	
Recommendations for the patient	<ul style="list-style-type: none"> • Avoid perpetuating and provoking factors • Stretch the muscles regularly and consistently (► Fig. 7.30) • Functional training: practice centering exercises for the glenohumeral joint regularly 	

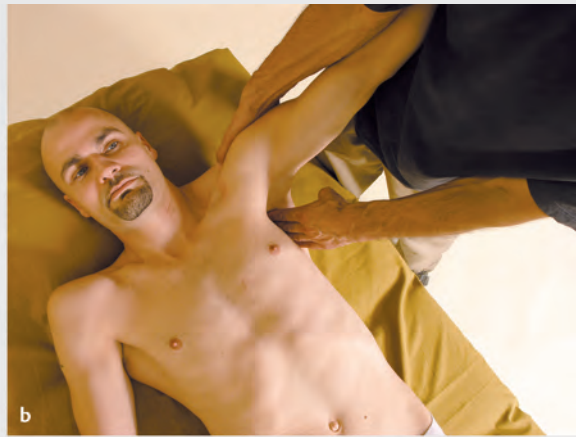

Fig. 7.26 Manual compression (technique I), stretching the TrP-region (technique II), and fascial stretching (technique III) over the lateral approach area: This is only possible after first treating the area between the subscapularis and serratus anterior using fascial separation (technique IV).

- a** The therapist's hand maneuvers enables to elevate and depress the scapula (over the therapist's right elbow) and to move it forward and backward. It also allows internal and external rotation of the humerus over the therapist's right hand.
- b** In cases of painful shoulder, the scapula can be brought forward using the therapist's hand in a flat position over the scapula.

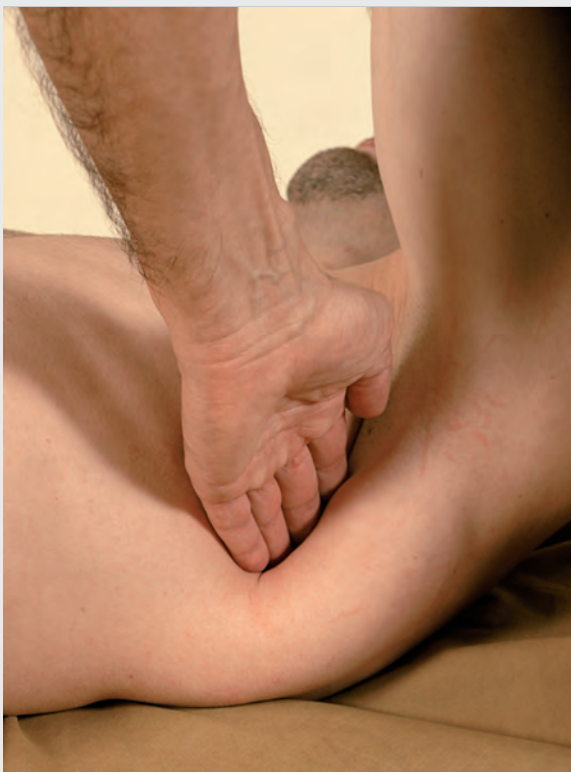

Fig. 7.27 Detail of fascial separation (technique IV) between the subscapularis and the serratus anterior (lateral approach).

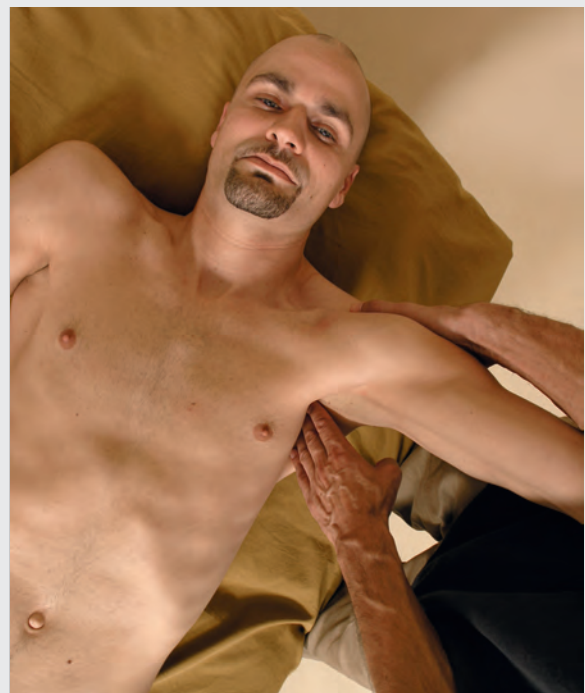


Fig. 7.28 In the distal area, the subscapularis is uncovered (Fig. 7.25), where a small part of the muscle is accessible to direct treatment with manual compression (technique I) or by means of stretching the TrP-region (technique II) (pretreatment with the fascial separation technique to the serratus anterior is therefore not necessary in this area).

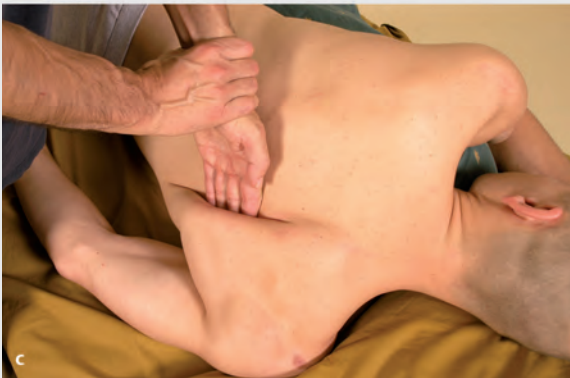
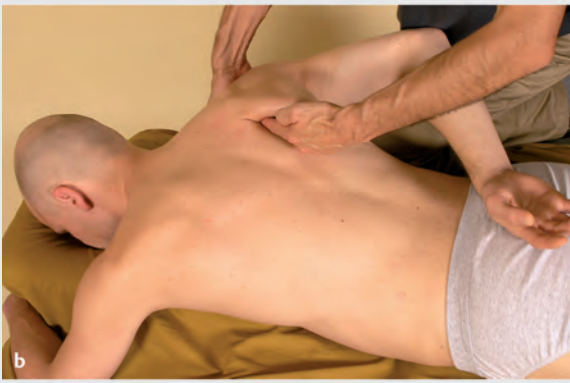
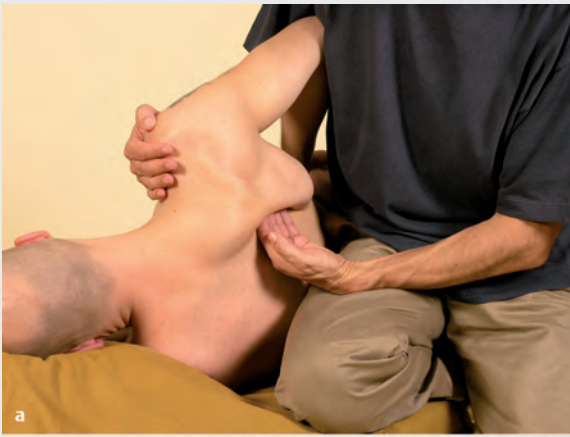Fig. 7.29 Manual compression (technique I), stretching the TrP-region (technique II), and fascial stretching (technique III) over the lateral approach area: Treatment of the subscapularis takes place through the fiber layers of the trapezius, rhomboids, and serratus anterior.

- a** Treatment in the lateral position with the affected side up.
- b** Treatment in the prone position.
- c** Treatment in the lateral position with the affected side down.



Fig. 7.30 Self-stretching (technique V).

- a** Initial position.
- b** Middle position.
- c** End position.